

Joint Replacement and Reconstruction Discharge Summary

Patient Name: Mr. JAISWAL PRAMOD
HARIPRASAD
Date Of Birth: 21/02/1959
Visit Code: IP0001
DOA: 01/06/2024

MRD#: 1365772

Sex: Male

DOD: 06/06/2024

Room/Bed No.: SS12B-4217

Consultant: Dr. WAKANKAR HEMANT (Regn No.:57705)

Reference: DR SUKRUT PURANDARE

Diagnosis: Osteoarthritis of both knees.

Clinical course and Event:

C/O: Pain in both knees, difficulty in walking, climbing stairs.

K/C/O: HYPOTHYROIDISM

O/E: Vitals - Normal, RS - Clear, CVS - NAD, P/A - Soft.

L/E: No Effusion, No PFT, MJLT ++, ROM R 0° - 0° L - 0° - 0°, Hips - Normal, No DNVC.

ASA Grade:

2

Pre op Hb: 14.9

Pre op PCV: 41.8

Pre op Sr Creat: 1.2

Pre op HbA1C: 5.8

Pre op EF: 60

Post op Hb: 11.6

Post op PCV: -

Post op Sr Creat: 0.7

Advice on Discharge:

1. T. ALTRADAY 1-0-0 x 15 days.
2. T. ULTRACET 0-0-1 x 7 days and then SOS
3. T. RIVABAN, 10 mg 0-0-1 x 14 days.
4. T. RESNER PLUS 0-0-1 x 1 month
5. T. TRICIUM ACTIVE 1-0-0 x 2 months.
6. T. ECOSPRIN 75 0-0-1 x To be started after completion of T. RIVABAN, x 3 months

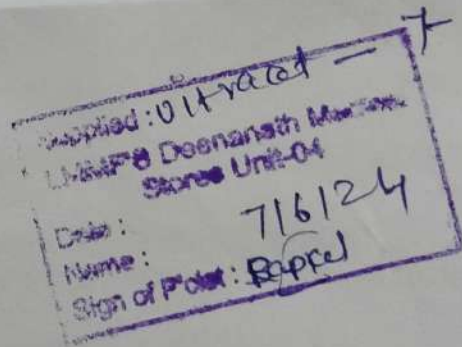
Following medicines to be continued as per Physician's advice

T ELTROXIN 100 mcg 1-0-0

T ELTROXIN 25 mcg 1-0-0 (Sat, Sun)

Recheck Sr. Ultra TSH after 6 weeks and Follow up in DMH medicine OPD

KNEE ROM ON DISCHARGE



RT	0	90
LT	0	90

Staple Removal on: 24/06/2024

Physiotherapy for 1 month after discharge:

Next follow up at Deenanath Mangeshkar Hospital, Pune 3 MONTHS

OPD Time: Mon and Wed 3 pm to 5 pm

With: Dr. Hemant Wakankar

By prior Appointment only. For appointment call 020-40151100 between 9 AM - 6 PM.

For emergency contact : Dept. ON Call no: 9850285871.

In case of emergency please come to DMH ER 1 (Emergency Room). It is open 24 hours a day.
Phone no.: 020-4015-1027 / 1065.

OPERATIVE NOTE

Pre-operative Antibiotics:

Inj. SUPACEF 1.5gm IV

Operative Procedure: Bilateral Total Knee Replacement

Date of Surgery: 3/06/2024 Type of Anaesthesia: SA+LA Anaesthetist: Dr. KHARE PRASANNA

Tourniquet inflated at 280 mm Hg for Rt -45 min, LT -47 min.

Midline incision. Arthrotomy through medial para patellar approach.

Patella: No degeneration. Patellar osteophytes excised.

ACL- Attenuated. PCL- Normal. Menisci- Degenerated.

Routine medial and posteromedial release done.

Distal femoral cut taken using intramedullary jig at 5°. Tibial cut with posterior 5° slope using extramedullary jig. Femoral sizing done using anterior referencing and femoral cutting block fixed in 3° of external rotation.

Flexion / Extension gaps balanced and mediolateral stability checked. Posterior release done.

Anterior and posterior chamfer cuts and box cuts completed. Trial prosthesis inserted. Joint stability and

patellofemoral tracking satisfactory. Lateral retinacular release not done/done. Femoral canal plugged with bone.

Trial prosthesis removed. Thorough joint wash given with normal saline pulsed lavage.

Tibial baseplate, Femoral prosthesis fixed with Palacos bone cement (Supacef 750 mg added).

Tourniquet released. Haemostasis achieved.

Tibial Poly inserted. Component stability and mediolateral stability reviewed.

Wound closed in layers without drain with Vicryl 1 and undyed Vicryl 2-0 and Staples.

The same procedure repeated on the other side.

Sterile dressing done.

DVT stockings given immediately post operatively.

Intraoperative PCV not given.

Inj. Tranexamic Acid (20 mg/kg) given at cementation and repeated at 3hrs and 6hrs.

LMWH started on the night of the surgery and continued till adequately mobilized.

Prosthesis Used - FREEDOM ,MAXX USA

Size - Right Left

Femur	E	E
Tibia	6	6
Poly	11mm PS	11mm PS

Post Operative Course:

Post operative pain controlled WITH LOCAL infiltration.

Inj. Supacef 750 mg IV X 2 doses.
ALL physiotherapy goals achieved.

Foleys cathether: No

ICU STAY: No

Blood Tranfusion: No

General advice after discharge:

List of Emergencies:

Fever, swelling, bleeding, redness, calf swelling, tightness, pain. Please come to hospital for urgent medical attention.

1. Not to wet the wound after surgery till sutures are removed.
2. Routine physiotherapy as per advice.
3. Start walking outdoor by 3 weeks.
4. Driving can be started after 6 weeks.
5. Do not start antibiotics on suspicion of infection without consulting the operating surgeon. Report to Deenanath Hospital joint replacement department.
6. Review with Dr. Hemant Wakankar after 3 months with prior appointment.
7. Zuprinor Skin patch applied on 03/06/2024. Do not apply heat in area of Zuprinor skin patch application. Remove patch on 11/06/2024. Remove patch early in case of excessive nausea, vomiting or giddiness.

Special needs

Physiotherapy:

For 1 month at home after surgery

Pain Relief:

Pain killers for 2 weeks , then as and when required

Dressing:

To be changed if soaked more than 50% in fresh blood

Name of Dr: KAUSTUBH B

Date: 06/06/2024

Designation: Assistant Doctor

Time: 10 AM

Investigation attached separately:

Please bring this card for Follow up:

apatil